

# On the myology of the cephalic region and pectoral girdle of three ariid species, *Arius heudeloti*, *Genidens genidens* and *Bagre marinus*, and comparison with other catfishes (Teleostei: Siluriformes)

Claudia Oliveira, Rui Diogo, Pierre Vandewalle and Michel chardon

Laboratory of Functional and Evolutionary Morphology,  
Bat. B6, University of Liège, B-4000 Sart-Tilman (Liège), Belgium

**ABSTRACT.** The muscles of the cephalic region and pectoral girdle of *Arius heudeloti*, *Genidens genidens* and *Bagre marinus* are described and compared with those of non-ariid siluriforms. Our observations and comparisons revealed that, although the configuration of the cephalic and pectoral girdle musculature of these ariid species is basically similar to that of other catfishes, these species present two myological peculiarities that could eventually represent autapomorphic characters of the family Ariidae, namely: 1) the muscle adductor arcus palatini inserts not only on the mesial margin of the suspensorium, but also on a significant part of the lateral surface of this complex structure; 2) the adductor mandibulae Aw is obliquely oriented, with its postero-dorsal fibres being significantly dorsal to the upper edge of the coronoid process.

**KEY WORDS:** Ariidae, *Arius heudeloti*, autapomorphies, *Bagre marinus*, catfish, cephalic region, comparative morphology, *Genidens genidens*, myology, pectoral girdle, Siluriformes.

## INTRODUCTION

The Siluriformes are "one of the economically important groups of fresh and brackish water fishes in the world: in many countries, they form a significant part of inland fisheries; several species have been introduced in fish culture; numerous species are of interest to the aquarium industry where they represent a substantial portion of the world trade" (TEUGELS, 1996).

Among the 35 siluriform families (FERRARIS & DE PINNA, 1999), the family Ariidae, with approximately 121 species in 12 genera (TEUGELS, 1996), is surely one of the most studied (see, e.g., REGAN, 1911; STARKS, 1926; LYNN & MELLAND, 1939; MERRIMAN, 1940; BAMFORD, 1948; SRINIVASACHAR, 1958; HUBBS & MILLER, 1960; ALEXANDER, 1965; TILAK, 1965; ROSSEL, 1968; LUNDBERG, 1975, 1993; GOSLINE, 1977; DAN, 1980; TAVOLGA, 1962; SRINIVASA & LAKSHMI, 1984; GAYET, 1987, 1995; VAN NEER & GAYET, 1988; LAKSHMI &

SRINIVASA, 1989; GAUDANT, 1993; MO, 1991; ARRATIA, 1995; ARRATIA & GAYET, 1995; CIONE et al., 1996; LADICH & BASS, 1998; etc.). The Ariidae are found worldwide in tropical and subtropical regions. They form an important part of commercial catches in some areas, particularly in the Far East, being also used in aquaculture (TEUGELS, 1996). According to MO (1991), the Ariidae (excluding the Madagascar genus *Ancharius* transferred to Mochokidae) are defined by two uniquely derived features: 1) a greatly enlarged utricular otolith occupying a space formed by the prootic, pterotic and exoccipital bones and 2) an extensive superficial ossification on the ventral side of the complex vertebral centrum.

Despite the numerous studies dedicated to the ariids (see above), the myology of these fishes was never described in detail. This complicates not only the study of the functional morphology of these fishes, but also the study of the phylogenetic relationships between the Ariidae and the other catfish families.

The aim of this work is thus to describe in detail the muscles of the cephalic region (branchial apparatus

excluded) and pectoral girdle of three ariid species, *Arius heudeloti* (Valenciennes, 1840), *Genidens genidens* (Valenciennes, 1840) and *Bagre marinus* (Mitchill, 1815), and to compare these muscles with those of other catfishes, either studied by us or described in the literature, in order to pave the way for further anatomical, functional and phylogenetical studies on ariids, as well as on catfishes in general.

## MATERIAL AND METHODS

The fishes studied are from the collection of our laboratory, trypsin-cleared and alizarine-stained (t&a) or alcohol fixed (alc): 4 alc. *Arius heudeloti*, 1 alc. and 1 t&a *Bagre marinus*, 2 alc. *Genidens genidens*. Dissections and morphological drawings were made using a Wild M5 dissecting microscope equipped with a camera lucida.

The nomenclature of the cephalic muscles is mainly based on WINTERBOTTOM (1974). However, for the different adductor mandibulae sections, we follow DIOGO & CHARDON (2000a), since recent works have pointed out that, with respect to these sections, WINTERBOTTOM's nomenclature (1974) presents serious limitations (see GOSLINE 1989; DIOGO & CHARDON, 2000a). In relation to the muscles associated with the mandibular barbels – which were not studied by WINTERBOTTOM (1974) – we follow DIOGO & CHARDON (2000b). With respect to nomenclature of the pectoral girdle muscles, we follow DIOGO et al. (2001).

## RESULTS

In this section, we will describe the myology of the cephalic region and pectoral girdle of *Arius heudeloti*, *Genidens genidens* and *Bagre marinus*. It should be noticed that the abbreviations used in these figures refer mainly to the myological structures being described: for a detailed description of the osteological components of the cephalic region and pectoral girdle of ariid catfishes, see REGAN (1911), STARKS (1926), MERRIMAN (1940), BAMFORD (1948), SRINIVASACHAR (1958), HUBBS & MILLER (1960), ALEXANDER (1965), TILAK (1965), CHARDON (1968), ROSSEL (1968), LUNDBERG (1975, 1993), GOSLINE (1977), TAVOLGA (1962), SRINIVASA & LAKSHMI (1984), GAYET (1987, 1995), VAN NEER & GAYET (1988), LAKSHMI & SRINIVASA (1989), GAUDANT (1993), MO (1991), ARRATIA (1995), ARRATIA & GAYET (1995), CIONE et al., (1996), etc.

### *Arius heudeloti*

*Musculus adductor mandibulae* (*ad.mnd*). This muscle is differentiated in several sections. The external section, adductor mandibulae A1-ost (*ad.mnd.1-ost*), originates on the preopercular and quadrate and inserts on the postero-lateral surface of the angulo-articular (Fig. 1A). The

adductor mandibulae A2 (*ad.mnd.2*), which lies dorso-mesially to the adductor mandibulae A1-ost, attaches caudally to the preopercular, pterotic and sphenotic (Fig. 1A). Rostrally it attaches to the mesial surface of the angulo-articular, laterally to the adductor mandibulae A3'' (Fig. 2B). The adductor mandibulae A3'-d is differentiated into two bundles, adductor mandibulae A3'-d-1 (*ad.mnd.3'-d-1*) and adductor mandibulae A3'-d-2 (*ad.mnd.3'-d-2*). The adductor mandibulae A3'-d-1 originates on the hyomandibular and preopercular, mesially to the adductor mandibulae A2 (Fig. 1B), and inserts on the postero-

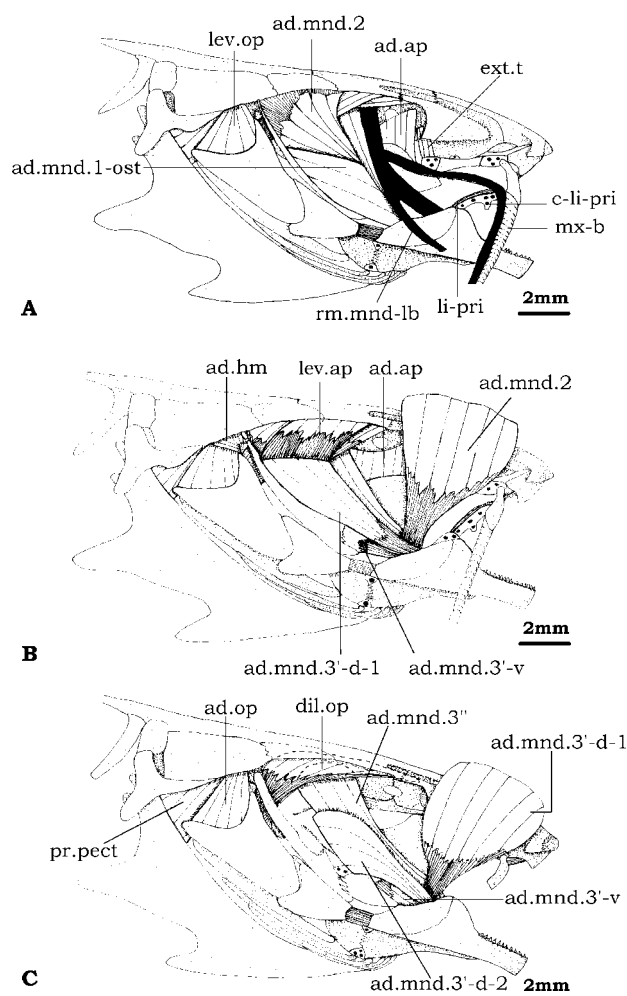


Fig. 1. – Lateral view of the cephalic musculature of *Arius heudeloti*. (A) All the muscles are exposed. (B) Levator operculi, adductor mandibulae A1-ost, ramus mandibularis and ramus maxillaris removed and adductor mandibulae A2 folded back. (C) Adductor mandibulae A2, adductor arcus palatini, levator arcus palatini, primordial ligament and adductor hyomandibularis removed and adductor mandibulae A3'-d-1 folded back. *ad.ap*, adductor arcus palatini; *ad.hm*, adductor hyomandibularis; *ad.op*, adductor operculi; *ad.mnd.1-ost*, *ad.mnd.2*, *ad.mnd.3'-d-1*, *ad.mnd.3'-d-2*, *ad.mnd.3'-v*, *ad.mnd.3''*, sections of adductor mandibulae; *c-li-pri*, cartilage associated with primordial ligament; *dil.op*, dilator operculi; *ext.t*, extensor tentaculi; *lev.ap*, levator arcus palatini; *lev.op*, levator operculi; *li-pri*, primordial ligament; *mx-b*, maxillary barbel; *pr.pect*, protractor pectoralis; *rm.mnd-lb*, lateral branch of ramus mandibularis.

dorso-mesial edge of the coronomeckelian bone (Fig. 2B). The adductor mandibulae A3'-d-2 (ad.mnd.3'-d-2), which lies antero-mesially to the adductor mandibulae A3'-d-1 (Fig. 1C), originates on a prominent, long lateral crest formed by both the quadrate and the hyomandibular and inserts on the postero-dorso-lateral edge of the coronomeckelian bone (Fig. 2C). The adductor mandibulae A3'-v (ad.mnd.3'-v) runs from the quadrate (Fig. 1B) to the mesial surface of the angulo-articular (Fig. 1C). The deeper bundle of the adductor mandibulae, adductor mandibulae A3'' (ad.mnd.3''), attaches anteriorly to the antero-lateral margin of the hyomandibular (Fig. 1C) and posteriorly to the medial surface of the angulo-articular (Fig. 2A). The smallest section of the muscle adductor mandibulae, the adductor mandibulae A $\omega$  (ad.mnd. $\omega$ ) is well-developed and obliquely oriented, running from the mesial side of the mandible to the tendons of both the adductor mandibulae A3'' and the adductor mandibulae A2 (Fig. 2A).

*Musculus levator arcus palatini (lev.ap)*. It originates on the dorso-lateral surfaces of both the sphenotic and the frontal and inserts on the lateral face of the hyomandibula (Fig. 1B).

*Musculus adductor arcus palatini (ad.ap)*. The adductor arcus palatini originates on the parasphenoid, orbitosphenoid and pterosphenoid. It inserts on the mesial margin of the hyomandibular, as well as on both the mesial and antero-dorsal surfaces of the metapterygoid (Fig. 1A, B).

*Musculus dilatator operculi (dil.op)*. Thick muscle situated medially to the levator arcus palatini (Fig. 1C). It runs from the sphenotic, pterosphenoid, frontal and lateral ethmoid to the antero-dorsal edge of the opercular (medial to the preopercular but lateral to the articulatory facet of the opercular for the hyomandibula) (Fig. 1C).

*Musculus levator operculi (lev.op)*. It originates on the ventro-lateral surface of the pterotic and inserts on the dorsal edge of the opercular (Fig. 1A).

*Musculus adductor hyomandibularis (ad.hm)*. Small muscle situated mesially to the levator operculi. It originates on the ventral surface of the pterotic and inserts on a well-developed postero-dorsal process of the hyomandibula (Fig. 1B).

*Musculus adductor operculi (ad.op)*. Situated mesially to the adductor hyomandibularis. It runs from the ventro-medial surface of the pterotic to the dorso-medial surface of the opercular (Fig. 1C).

*Musculus extensor tentaculi (ext.t)*. It originates on the antero-medial surface of both the lateral ethmoid and the orbitosphenoid (Fig. 1A). It inserts on the mesial and ventral surfaces of the entopterygoid, as well as on the back of the autopalatine (Fig. 1A).

*Musculus protractor hyoidei (pr.h)*. This muscle is differentiated into three parts. The pars ventralis (pr.h-v), in which are lodged the moving parts of the cartilages asso-

ciated with the mandibular barbels, originates on both the anterior and posterior ceratohyals and inserts on the dentary, meeting its counterpart in a well-developed median aponeurosis (Fig. 3A). The pars lateralis (pr.h-l) originates on the posterior ceratohyal, inserting on the ventro-medial face of the dentary (Fig. 3A). The pars dorsalis (pr.h-d) runs from the anterior ceratohyal to the dentary (Fig. 3A).

*Intermandibularis (intm)*. Well-developed muscle joining the two mandibles (Fig. 3A).

*Musculus retractor externi mandibularis tentaculi (r.ex.mnd.t)*. It runs from the moving part of the cartilage associated with the outer mandibular barbel to the dentary (Fig. 3A).

*Musculus retractor interni mandibularis tentaculi (r.in.mnd.t)*. It originates on the moving part of the cartilage associated with the internal mandibular barbel and inserts on dentary (Fig. 3A).

*Musculus protractor externi mandibularis tentaculi (pr.ex.mnd.t)*. It runs from the posterior ceratohyal to the moving part of the cartilage associated with the outer mandibular barbel (Fig. 3A).

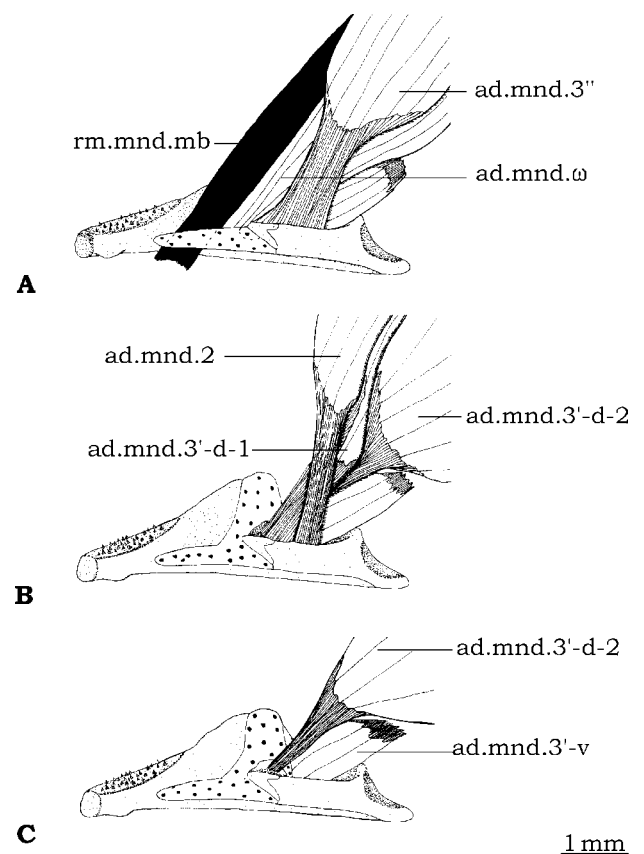


Fig. 2. – Mesial view of the mandible and adductor mandibulae muscle of *Arius heudeloti*. (A) Adductor mandibulae complex exposed. (B) Adductor mandibulae A3'', adductor mandibulae A $\omega$  and ramus mandibularis removed. (C) Adductor mandibulae A2 and adductor mandibulae A3'-d-1 removed. ad.mnd.2, ad.mnd.3'-d-1, ad.mnd.3'-d-2, ad.mnd.3'-v, ad.mnd.3'', ad.mnd. $\omega$ , sections of adductor mandibulae; rm.mnd-mb, mesial branch of ramus mandibularis.

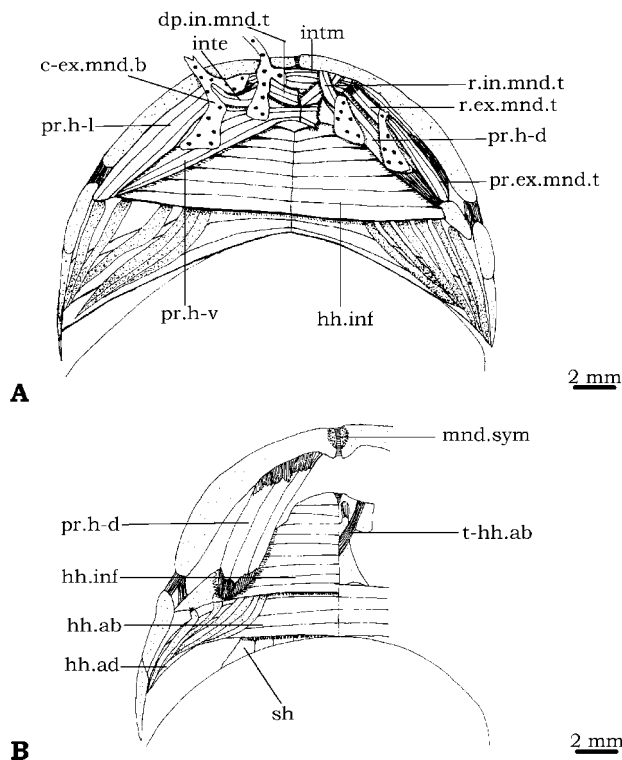


Fig. 3. – Ventral view of the cephalic musculature of *Arius heudeloti*. (A) On the left side all muscles are exposed, on the right side lateral and ventral sections of protractor hyoideus and intertentacularis removed and cartilages associated with mandibular barbels were folded back. (B) On the left side only the hyohyoideus abductor, dorsal section of protractor hyoideus, hyohyoideus adductor, hyohyoideus inferioris and sternohyoideus are represented, on the right side only the hyohyoideus abductor is represented. *c-ex.mnd.b*, cartilage associated with the external mandibular barbel; *dp.in.mnd.t*, depressor interni mandibularis tentaculi; *hh.ab*, hyohyoideus abductor; *hh.ad*, hyohyoideus adductor; *hh.inf*, hyohyoideus inferioris; *inte*, intertentacularis; *intm*, intermandibularis; *mnd.sym*, mandibular symphysis; *pr.ex.mnd.t*, protractor exteni mandibularis tentaculi; *pr.h-d*, *pr.h-l*, *pr.h-v*, dorsal, lateral and ventral sections of protractor hyoideus; *r.ex.mnd.t*, retractor externi mandibularis tentaculi; *r.in.mnd.t*, retractor interni mandibularis tentaculi; *sh*, sternohyoideus; *t-hh.ab*, tendon of hyohyoideus abductor.

*Musculus depressor interni mandibularis tentaculi* (*dp.in.mnd.t*). Small muscle extending from a mesial aponeurosis to the mesial surface of the cartilage associated with the internal mandibular barbel (Fig. 3A). *Intertentacularis* (*inte*). Small muscle running from the mesial face of the cartilage associated with the external mandibular barbel to the lateral face of that associated with the internal one (Fig. 3A).

*Musculus hyohyoideus inferior* (*hh.inf*). Thick muscle attaches laterally on the ventral surface of the ceratohyals and medially on a median aponeurosis (Fig. 3A, B).

*Musculus hyohyoideus abductor* (*hh.ab*). It runs from the first (medial) branchiostegal ray to a median aponeurosis, which is associated with two long, strong tendons,

attached, respectively, to the two ventral hypohyals (Fig. 3B).

*Musculus hyohyoideus adductor* (*hh.ad*). Medially it attaches to the first (medial) branchiostegal ray and laterally it attaches to the opercular (Fig. 3B).

*Musculus sternohyoideus* (*sh*). Well-developed muscle running from the parurohyal to both the anterior and the antero-dorsal surfaces of the cleithrum (Fig. 4A).

*Musculus arrector dorsalis* (*arr.d*). This muscle is differentiated into two well-developed divisions. The dorsal division (*arr.d-dd*), situated on the dorsal surface of the pectoral girdle, originates on the dorso-mesial edge of the scapulo-coracoid (Fig. 4A) and inserts on the anterior edge of the dorsal condyle of the pectoral spine. The ventral division (*arr.d-vd*), situated on the ventral surface of the pectoral girdle, originates on the ventral margin of the cleithrum and inserts on the antero-lateral edge of the pectoral spine (Fig. 4B).

*Arrector ventralis* (*arr.v*). It runs from the antero-ventral surface of the cleithrum to the ventral condyle of the pectoral spine (Fig. 4B).

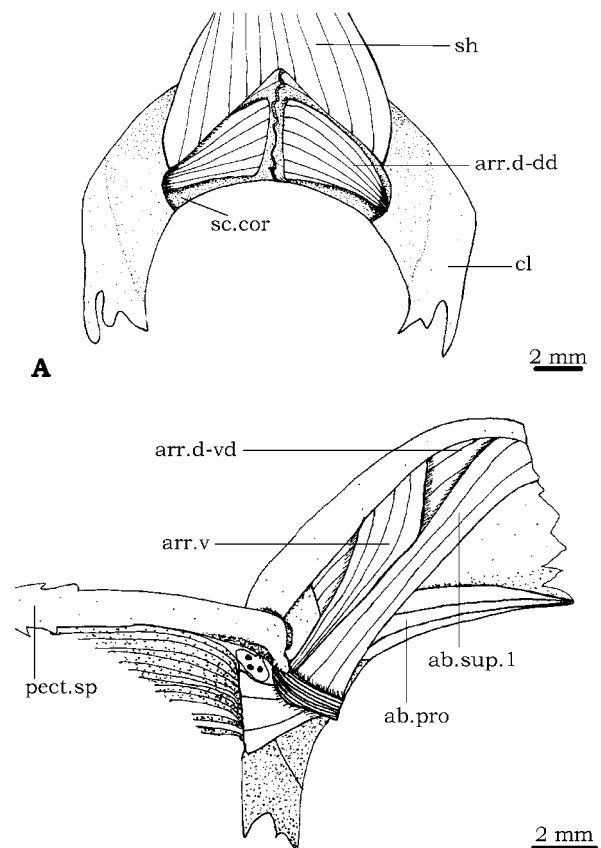


Fig. 4. – Pectoral girdle musculature of *Arius heudeloti*. (A) Dorsal view. (B) Ventral view. *ab.pro*, abductor profundus; *ab.sup.1*, section 1 of abductor superficialis; *arr.d-dd*, *arr.d-vd*, dorsal and ventral divisions of arrector dorsalis; *arr.v*, arrector ventralis; *cl*, cleithrum; *pec-sp*, pectoral spine; *sc.cor*, scapulo-coracoid; *sh*, sternohyoideus.

*Abductor profundus* (*ab.pro*). It originates on the postero-mesial edge of the coracoid (Fig. 4B) and inserts on the mesial surface of the dorsal condyle of the pectoral spine.

*Abductor superficialis* (*ab.sup*). Paired. This muscle is differentiated in two sections. The larger section (Fig. 4B : *ab.sup.1*) attaches medially to the ventral face of both the cleithrum and the scapulo-coracoid and laterally to the antero-ventral margin of the ventral part of the pectoral fin rays. The smaller section runs from the postero-lateral edge of the scapulo-coracoid to the antero-dorsal margin of the ventral part of the pectoral fin rays.

*Adductor superficialis*. This muscle is also differentiated into two sections. The larger one originates on the posterior surfaces of both the cleithrum and the scapulo-coracoid and inserts on the antero-dorsal margin of the dorsal part of the pectoral fin rays. The smaller section runs from the ventro-lateral edge of the mesocoracoid arch and the dorsal surface of the proximal radials to the antero-ventral margin of the dorsal part of the pectoral fin rays.

### *Genidens genidens*

In a general way, the configuration of the muscles of the cephalic region and pectoral girdle of this species resembles that of *Arius heudeloti*. The most significant differences between these species are: I) in *G. genidens* (Fig. 5) the adductor mandibulae A1-ost (*ad.mnd.1-ost*) contacts a significant part of the lateral surface of the angulo-articular, inserting on a prominent lateral crest of this bone (Fig. 5A, compare with Fig. 1A); II) in *G. genidens* the levator operculi (*lev.op*) and the adductor hyomandibularis (*ad.hm*) are not only originated on the pterotic, but also on the posttemporo-supracleithrum (Fig. 5A, B, compare with Fig. 1A, B).

### *Bagre marinus*

With the exception of a few differences, the configuration of the cephalic and pectoral girdle musculature of *Bagre marinus* also resembles that of *Arius heudeloti*. Most of these differences are related to the fact that *B. marinus* only presents one, and not two, mandibular barbels on each side of the head. Therefore, contrarily to *A. heudeloti* (Fig. 3A), which presents five little muscles on each side of the head exclusively related with the movement of the mandibular barbels (retractor externi mandibularis tentaculi, retractor interni mandibularis tentaculi, protractor externi mandibularis tentaculi, depressor interni mandibularis tentaculi and intertentacularis), in *B. marinus* there is only one muscle associated with the single mandibular barbel in each side of the head. Although this muscle seems to be a retractor of this barbel, it is difficult to specify whether it corresponds to the retractor externi mandibularis tentaculi or to the retractor interni mandibularis tentaculi, due to the incertitude concerning the identity of the mandibular barbels of *B. marinus* (that

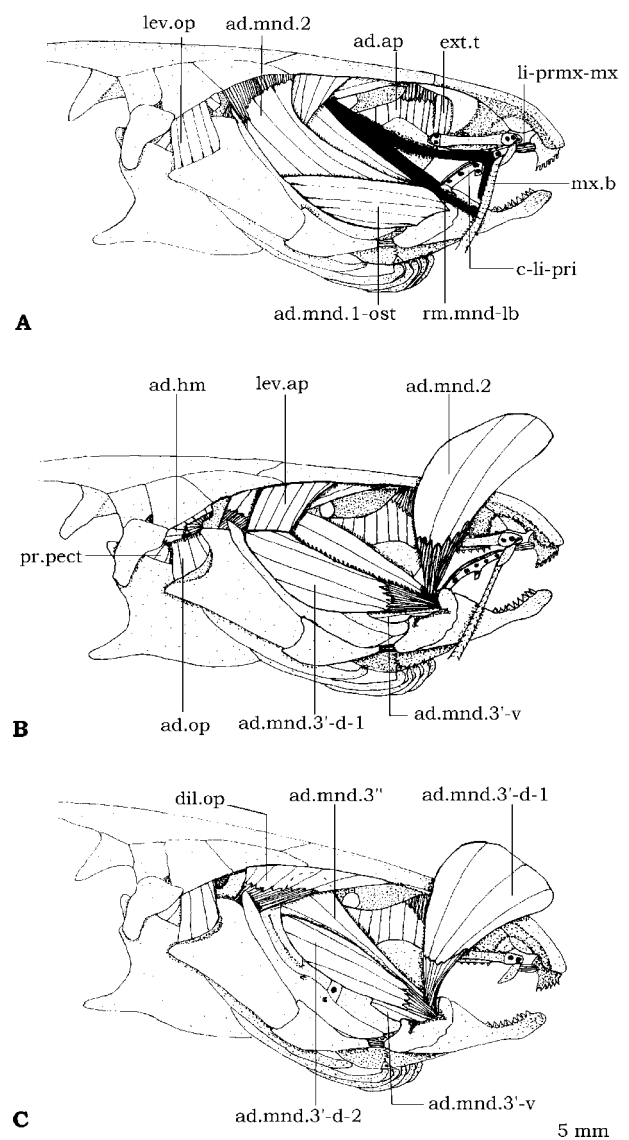


Fig. 5. – Lateral view of the cephalic musculature of *Genidens genidens*. (A) All the muscles are exposed. (B) Levator operculi, adductor mandibulae A1-ost, ramus mandibularis and ramus maxillaris removed and adductor mandibulae A2 folded back. (C) Adductor mandibulae A2, levator arcus palatini, primordial ligament and adductor hyomandibularis removed and adductor mandibulae A-3'-d-1 folded back. *ad.ap*, adductor arcus palatini; *ad.hm*, adductor hyomandibularis; *ad.op*, adductor operculi; *ad.mnd.1-ost*, *ad.mnd.2*, *ad.mnd.3'-d-1*, *ad.mnd.3'-d-2*, *ad.mnd.3'-v*, *ad.mnd.3''*, sections of adductor mandibulae; *c-li-pri*, cartilage associated with primordial ligament; *dil.op*, dilator operculi; *ext.t*, extensor tentaculi; *lev.ap*, levator arcus palatini; *lev.op*, levator operculi; *li-prmx-mx*, ligament between premaxillary and maxillary; *mx-b*, maxillary barbel; *pr.pect*, protractor pectoralis; *rm.mnd-lb*, lateral branch of ramus mandibularis.

is, whether these barbels correspond to the external or to the internal mandibular barbels of other catfishes: see DIOGO & CHARDON, 2000b).

In addition to the differences related to the mandibular barbels, there is another significant difference between *B. marinus* and *A. heudeloti*: in *B. marinus*, as it is the case

in *G. genidens*, the adductor mandibulae A1-ost contacts a significant part of the lateral surface of the angulo-articular, inserting on a lateral crest of this bone (which, however, is not as developed as in *G. genidens*).

## DISCUSSION

In a general way, the muscles of the cephalic region and pectoral girdle of *Bagre marinus*, *Arius heudeloti* and *Genidens genidens* present a quite similar configuration. The most remarkable difference between the cephalic and pectoral girdle musculature of these three species is surely the configuration of the muscles associated with the mandibular barbels. In fact, *A. heudeloti* and *G. genidens*, which present on each side of the head several (five in this specific case) little muscles associated with the movements of the two mandibular barbels, exhibit a quite similar configuration to that found in many other catfishes, such as claroteids, amphiliins, doumeins, bagrids, clariids, plotosids or malapterurids (see DIOGO & CHARDON, 2000b). However, in *B. marinus*, contrarily to these two species, there is only one mandibular barbel and one little muscle associated to it in each side of the head. This muscle seems to be a retractor of the mandibular barbel, since it attaches anteriorly to the mandible and posteriorly to the antero-dorsal surface of the moving part of the cartilage associated with this barbel (see DIOGO & CHARDON, 2000b). However, the present study did not enable us to determine which of the two pairs of mandibular barbels present in most other catfishes (externals mandibular barbels and internal mandibular barbels) corresponds to the single pair found in *B. marinus*. Therefore, it could not be specified if this muscle is a retractor externi mandibularis tentaculi or a retractor interni mandibularis tentaculi. Another significant difference between the cephalic and pectoral girdle muscles of the three ariid species studied is that in both *B. marinus* and *G. genidens*, but not in *A. heudeloti*, the adductor mandibulae A1-ost contacts a great part of the lateral surface of the angulo-articular. A remarkable difference between these three species is also that in *G. genidens* the levator operculi and adductor hyomandibularis are associated with both the pterotic and the posttemporo-supracleithrum, and not only with the pterotic, as it is the case in *A. heudeloti* and *B. marinus*.

As referred to in the Introduction, one of the principal aims of this work is to compare the configuration of the cephalic and pectoral girdle musculature of the three ariid species studied and that of other siluriforms (either studied by us or described in the literature). This comparison revealed that, in a general way, the muscles of the cephalic region and pectoral girdle of *A. heudeloti*, *B. marinus* and *G. genidens* do not differ much from those of most other catfishes in which these muscles have been studied in detail. However, there are three morphological features, which are present in all the three ariid species studied, that, by their rarity, deserve particular attention, being discussed below.

As pointed out by DIOGO & VANDEWALLE (in press), the plesiomorphic condition for catfishes is that in which the adductor arcus palatini inserts on the mesial margin of the suspensorium. However, in the three ariid species studied, *A. heudeloti* (Fig. 1A), *G. genidens* (Fig. 5A) and *B. marinus*, this muscle not only inserts on the mesial margin of both the hyomandibular and the metapterygoid, but also on a significant part of the lateral surface of the metapterygoid. Since such a configuration of the adductor arcus palatini muscle is found in all the three ariid species studied, and in no other catfish studied by us or described in the literature, this morphological feature could represent an ariid autapomorphy. However, it should be noted that much more data on the configuration of this muscle in other ariid species, as well as in many other catfishes, are needed to eventually confirm this hypothesis.

Plesiomorphically in catfishes the adductor mandibulae A $\omega$  is a small, anteroposteriorly-oriented bundle lodged in the mesial surface of the mandible (see DIOGO & CHARDON, 2000a). However, in the three ariid species studied, *A. heudeloti* (Fig. 2A), *G. genidens* and *B. marinus*, the adductor mandibulae A $\omega$  is a well-developed, obliquely-oriented bundle, with its postero-dorsal fibers being significantly dorsal to the upper edge of the coronoid process. The presence of such a configuration of the A $\omega$  in all the three ariid species studied, together with its absence in all other catfish studied by us and/or described in the literature, indicates that this configuration could probably represent an ariid autapomorphy. However, as mentioned above, much more data on the configuration of this muscle in other ariid species, as well as in many other catfishes, are needed to eventually confirm this hypothesis.

In catfishes the adductor operculi connects the neurocranium, the mesial surface of the opercular and, often (e.g., in amphiliins, plotosids, bagrids, diplomystids, clariids, schilbeids), the mesial surface of the hyomandibular (DIOGO & VANDEWALLE, in press). However, in the three ariid species studied, as well as in the auchenoglanidin and clarotein species examined in this work, in the region normally occupied by the adductor operculi, in addition to this muscle there is a small, completely separate muscle (here called adductor hyomandibularis) running from the neurocranium to the postero-dorsal surface of the hyomandibular (see, e.g., Figs 1B, 5B). As the adductor hyomandibularis is found not only in the ariid, but also in the auchenoglanidin and the clarotein species examined, its presence could not constitute an ariid autapomorphy, that is, a derived feature exclusively present in the ariids. Instead, the presence of the adductor hyomandibularis in these three groups seems to support DIOGO et al.'s (in press) study, according to which the auchenoglanidins, ariids and claroteins are probably closely related.

## ACKNOWLEDGEMENTS

We wish to thank Dr J. T. Williams, Dr S. J. Jewett and Dr R. Vari (NMNH), Dr G. Hureau and Dr G. Duhamel (MNHN),

Dr P. Lal     (UNB), Dr M. De Troch (UG) and Dr G. Teugels (MRAC) for kindly providing a large part of the specimens studied in this work and for valuable discussions. We are also pleased to acknowledge the helpful criticism, advice and assistance of R. P. Vari, D. Adriaens, T. X. Abreu, F. Wagemans, E. Parmentier, M. Gayet and L. Taverne. This project received financial support from the following grant to R. Diogo: PRAXIS XXI/BD/19533/99 ("Fund    o para a Ci  ncia e a Tecnologia", Portuguese Government).

## REFERENCES

- ALEXANDER, R.McN. (1965). Structure and function in catfish. *J. Zool. (Lond.)*, 148: 88-152.
- ARRATIA, G. (1995). Morphology of the lateral line system and of the skin of diplomystid and certain primitive loricarid catfishes and systematic and ecological considerations. *Bonn. Zool. Monogr.*, 36: 5-109.
- ARRATIA, G. & M. GAYET (1995). Sensory canals and related bones of Tertiary siluriform crania from Bolivia and North America and comparison with recent forms. *J. Vert. Paleont.*, 15: 482-505.
- BAMFORD, B.T.W. (1948). Cranial development of *Galeichthys felis* (Ariidae). *Proc. Zool. Soc. (Lond.)*, 118: 364-391.
- CIONE, A.L., M.M. AZPELICUETA & G. CAILLE (1996). An ariid catfish from marine middle Miocene beds of Patagonia. Recent ariid biogeography in southern South America. *Rev. Espanola Paleont.*, 11: 11-17.
- DAN, S.S. (1980). Age and growth in the catfish *Tachysurus tenuispinis*. *Indian J. Fisheries*, 27: 220-235.
- DIOGO, R. & M. CHARDON (2000a). Homologies Between Different Adductor Mandibulae Sections of Teleostean Fishes, with a Special Regard to Catfishes (Teleostei: Siluriformes). *J. Morphol.*, 243: 193-208.
- DIOGO, R. & M. CHARDON (2000b). The structures associated with catfish (Teleostei: Siluriformes) mandibular barbels: Origin, Anatomy, Function, Taxonomic distribution, Nomenclature and Synonymy. *Neth. J. Zool.*, 50: 455-478.
- DIOGO, R. & P. VANDEWALLE (in press). A review of the superficial cranial musculature of catfishes (Teleostei: Siluriformes), with comments on plesiomorphic states. In: KAPOOR, B.G., G. ARRATIA, M. CHARDON & R. DIOGO (eds.), *Catfishes*. Oxford & IBH Publishing and Science Publishers, New Delhi and New Hampshire.
- DIOGO, R., C. OLIVEIRA & M. CHARDON (2001). On the osteology and myology of catfish pectoral girdle, with a reflection on catfish (Teleostei: Siluriformes) plesiomorphies. *J. Morphol.*, 248: 100-125.
- DIOGO, R., P. VANDEWALLE & M. CHARDON (in press). Osteology and myology of the cephalic region and pectoral girdle of the Chinese catfish *Cranoglanis boudierius*, with a discussion on the autapomorphies and phylogenetic relationships of the Cranoglanididae (Teleostei: Siluriformes). *J. Morphol.*, 248: 100-125.
- FERRARIS, C.J. & M.C.C. DE PINNA (1999). Higher-level names for Catfishes (Actinopterygii: Ostariophysi: Siluriformes). *Proc. Calif. Acad. Sci.*, 51: 1-17.
- GAUDANT, J. (1993). Paleoiichthyogeographie, Paleobiologie et Migrations intercontinentales: remarques critiques. *Bull. Soc. Geol. France*, 164: 861-864.
- GAYET, M. (1987). Lower vertebrates from the early-middle Eocene kuldana formation of Kohat (Pakistan): Holostei and Teleostei. *Contr. Mus. Paleont. Univ. Mich.*, 27: 151-193.
- GAYET, M. (1995). A propos des Ostariophysaires (Poissons, Teleosteens). *Bull. Soc. Zool. (Paris)*, 120: 347-360.
- GOSLINE, W.A. (1977). The structure and function of the dermal pectoral girdle in bony fishes with particular reference to ostariophysines. *J. Zool. (Lond.)*, 183: 329-338.
- GOSLINE, W.A. (1989). Two patterns of differentiation in the jaw musculature of teleostean fishes. *J. Zool. (Lond.)*, 218: 649-661.
- HUBBS, C.L. & M.M. MILLER (1960). *Potamarius*, a new genus of ariid catfishes from the fresh waters of Middle America. *Copeia*, 2: 101-112.
- LADICH, F. & H.A. BASS (1998). Sonic/vocal motor pathways in catfishes: comparisons with other teleosts. *Brain, Behav. Evol.*, 51: 315-330.
- LAKSHMI, K. & R. SRINIVASA (1989). Postcranial skeleton of the marine catfish *Arius tenuispinis*. *J. Morphol.*, 202: 361-377.
- LUNDBERG, J.G. (1975). Homologies of the upper shoulder girdle and temporal region bones in catfishes (Order Siluriformes), with comments on the skull of the Helogeneidae. *Copeia*, 1975: 66-74.
- LUNDBERG, J.C. (1993). African-South American freshwater fish clades and continental drift: problem with a paradigm. In: P. GOLDBLATT (ed.), *Biological relationships between Africa and South America*. Yale University Press, New Haven: 156-199.
- LYNN, W.G. & A.M. MELLAND (1939). A fossil catfish (*Fellichthys staurus*) from the Maryland Miocene. *J. Wash. Acad. Sci.*, 29: 14-20.
- MERRIMAN, D. (1940). Morphological and embryological studies on two species of marine catfish, *Bagre marinus* and *Galeichthys felis*. *Zoologica*, 25: 221-248.
- MO, T. (1991). Anatomy, relationships and systematics of the Bagridae (Teleostei: Siluroidei) with a hypothesis of siluroid phylogeny. *Theses Zoologicae*, 17: 1-216.
- REGAN, C.T. (1911). The classification of the teleostean fishes of the order Ostariophysi: 2. Siluroidea. *Ann. & Mag. Nat. Hist.*, 8: 553-577.
- ROSSEL, F. (1968). Funktionsmorphologische Untersuchungen An Welsen (Teleostei, Siluriformes) – Zum Problem des Lebensformtypus. Unpubl. Ph.D. thesis, Frankfurt Univ., Frankfurt. 221 pp.
- SRINIVASACHAR, H.R. (1958). Development of the skull in catfishes. Part V. Development of skull in *Heteropneustes fossilis*. *Proc. Nat. Inst. Sci. India*, 248: 165-190.
- SRINIVASA, R. & K. LAKSHMI (1984). Head skeleton of the marine catfish *Arius tenuispinis* Day (Osteichthyes: Siluriformes, Ariidae). *J. Morphol.*, 118: 221-238.
- STARKS, E.C. (1926). Bones of the ethmoid region of the fish skull. *Stanford Univ. Publ., Univ. Ser., Biol. Sci.*, 4: 139-338.
- TAVOLGA, W.N. (1962). Mechanisms of sound production in the ariid catfishes *Galeichthys* and *Bagre*. *Bull. Amer. Mus. Nat. Hist.*, 124: 5-30.
- TAYLOR, W.R. & G.C. VAN DYKE (1985). Revised procedure for staining and clearing small fishes and other vertebrates for bone and cartilage study. *Cybiurn*, 2: 107-119.

- TEUGELS, G.G. (1996). Taxonomy, phylogeny and biogeography of catfishes (Ostariophysi, Siluroidei): an overview. *Aquat. Living Resour.*, 9: 9-34.
- TILAK, R. (1965). The comparative morphology of the osteocranium and the Weberian apparatus of Tachysuridae (Pisces: Siluroidei). *J. Zool. (Lond.)*, 146: 150-174.
- VAN NEER, W. & M. GAYET (1988). Etude des poissons en provenance des sites holocènes du bassin de Taoudenni-Araouane (Mali). *Bull. Mus. Nat. Hist. Nat. (Paris)*, 10: 343-383.
- WINTERBOTTOM, R. (1974). A descriptive synonymy of the striated muscles of the Teleostei. *Proc. Acad. Nat. Sci. (Phil.)*, 125: 225-317.

*Received: February 11, 2001*

*Accepted: July 19, 2001*