

Research Note

Quantifying spirorchiid eggs in splenic histological samples from green turtles

F. D'AZEREDO^{1*}, M. MEIRA-FILHO¹, T. M. WORK²

¹Econserv Diagnóstico e Consultoria, Pontal do Paraná – PR, 83255-000, Brazil, *E-mail: felipedtorres@gmail.com;
²US Geological Survey, National Wildlife Health Center, Honolulu Field Station, PO Box 50167, Honolulu, HI 96850, USA

Article info

Received January 12, 2019
Accepted May 9, 2019

Summary

The present study proposes a new methodology for the quantification of parasite eggs in animal tissue. Quantification of parasites are important to understand epidemiology of spirorchiid infections in sea turtles, however different methodologies for quantifying Spirorchiidae eggs in turtle tissues have been used. The most representative way to quantify Spirorchiidae burdens in tissues is counting eggs / g of tissue, however, this method is very laborious. As an alternative, we propose quantifying number of Spirorchiidae eggs/ area of tissue on a microscope slide. We compared this method to number of eggs / slide, a common metric of egg burden in turtle tissues. Both methods correlated well with eggs / g with eggs/mm² of tissue having better correlation.

Keywords: *Chelonia mydas*; helminth; pathology

Introduction

The green turtle, *Chelonia mydas*, is distributed worldwide, occurring from tropical regions to temperate zones. The green turtle forages in coastal habitats (Hirth, 1997) and according to Seminoff (2004), is listed as endangered or near-threatened in portions of its range. In Hawaii, green turtles have been recovering since protection was established in the early 1970s (Balazs & Chaloupka, 2004).

Spirorchiidae are a group of parasitic trematodes found in the circulatory system of marine and freshwater turtles (Platt, 2002) comprising 96 species in 22 genera of which ten are unique to sea turtles (WoRMS, 2018). Spirorchiidae infections are often associated with stranding and mortality of sea turtles worldwide and tend to be more severe in debilitated turtles (Stacy *et al.*, 2010). However, the actual impact of these parasites on the health of these animals is not entirely known (Goldberg *et al.*, 2013). Adult helminths infect the vascular system, primarily the heart, as well

as vessels of various internal organs and mesenteries. There, they copulate and oviposit, causing vasculitis, parasitic granulomas and thromboses (Aguirre *et al.*, 1998). Commonly affected tissues are the gastrointestinal tract, liver, spleen, lung and central nervous system (Glazebrook & Campbell, 1981); however, Goodchild and Dennis (1967) found that the spleen is the organ of *Chrysemys picta* most commonly infected by Spirorchiidae eggs, and similar observations were made by Flint *et al.* (2009), in green turtles. The spleen is also heavily infected in *C. caretta* (Ribeiro *et al.*, 2017). The detection of infections caused by Spirorchiidae in turtles is usually made during necropsy, when adult helminths or eggs can be observed grossly or microscopically (Work *et al.*, 2005). Parasites can be identified through morphometric analysis of adult helminths, and more recently molecular means (Chapman *et al.*, 2017). However, decomposition is a limiting factor in the detection of these parasites at necropsy, because adults are difficult to detect in decomposed tissues. In contrast, parasite eggs and their shells are more numerous in tissues and, relative to adults,

* – corresponding author

more resistant to degradation thereby acting as a more durable indicator of infestation (Chen *et al.*, 2012). Other studies have detected turtles infected with Spirorchiidae eggs in the absence of the adult worm, which seems to confirm this impression (Aguirre *et al.*, 1998; Santoro *et al.*, 2007; Flint *et al.*, 2010).

The lesions caused by Spirorchiidae eggs are well described and are characterized by the formation of granulomas with giant cell infiltrations (Wolke *et al.*, 1982; Gordon *et al.*, 1998; Work *et al.*, 2005; Flint *et al.*, 2009; Flint *et al.*, 2010; Marchiori *et al.*, 2017; Ribeiro *et al.*, 2017; Santoro *et al.*, 2017; Werneck *et al.*, 2017). Severe forms of the disease are generally associated with other problems such as fibropapillomatosis, coccidiosis and generalized infections with Gram-negative bacteria (Gordon *et al.*, 1998; Raidal *et al.*, 1998), but few studies exist attempting to relate parasite burdens to health outcomes. One exception is a study showing a negative relationship between tissue spirorchiid egg burden and body condition in green turtles from Hawaii (Work *et al.*, 2005). In cases of intestinal impaction, it was observed that in most cases, animals were concomitantly infected with moderate to severe burdens of spirorchids (Flint *et al.*, 2010). When found in low amounts, Spirorchiidae infections are considered incidental for healthy populations of sea turtles (Flint *et al.*, 2010).

Different methodologies for quantifying Spirorchiidae eggs in turtle tissues have been used. Goodchild and Dennis (1967) proposed an egg counting by histological section, regardless of the area, a method also used by Ribeiro *et al.* (2017). Stacy *et al.* (2010) created subjective scores for infection intensity of Spirorchiidae eggs, ranging from 0 to 3 according to the amount of egg masses seen in tissue sections. Flint *et al.* (2010) presented a similar methodology, scoring severity of spirorchiid infection from 0 to 3 (absent, mild, moderate or severe) based on presence of <5 or >5 eggs per 20X microscope field. This methodology was also used by Santoro *et al.* (2017) and Werneck *et al.* (2017). Whilst useful empirically, none of these methods relate egg counts to actual area or mass of tissue examined, making cross-study comparisons difficult. A more rigorous assessment of parasite burden was done by quantifying eggs per gram of spleen (Work *et al.*, 2005), a technique adapted

from quantifying spirorchiid eggs in tumors (Dailey & Morris, 1995). Whilst quantifying eggs per unit weight of tissue might yield more robust results, quantifying eggs/g of tissue is laborious, requiring tissue digestion and extensive filtration. Quantifying eggs in tissue sections would be an attractive alternative as this is less laborious, however, these counts would need to be validated to a more stringent sampling regimen (e.g. eggs/g). Here we investigated how egg burden relativized to surface area of tissues related to eggs/g of spleen (GOS) using tissues from stranded Hawaiian green turtles.

Material and Methods

Tissues for this study originated from turtles stranded in Hawaii with various conditions in Hawaii (Work *et al.*, 2004). Forty randomly selected formalin- fixed spleens that had previously been quantified for egg burdens (Work *et al.*, 2005) were selected for this study. Spleens were embedded in paraffin, sectioned at 5 um, and stained with hematoxylin and eosin. Tissue sections (one section per individual) were examined under light microscopy and number of eggs in the section was counted. The slides were then scanned, and Image J (Schneider *et al.*, 2012) was used to calculate the area of tissue quantified (mm²). This allowed calculation of number of eggs/mm² of tissues which was then related to eggs/g of GOS (Work *et al.*, 2005) using linear regression.

Ethical Approval and/or Informed Consent

National Oceanic and Atmospheric Administration National Marine Fisheries Permit 16865, US Fish and Wildlife Service endangered species permit BRD-VETAGENT-8, and CITES permit 17US105568/9.

Results

Means of 243.4 ± 238.7 (2.0 - 1014.0) eggs per section and 1.7 ± 1.9 (0.0 - 7.7) eggs per mm² were found in the splenic tissues

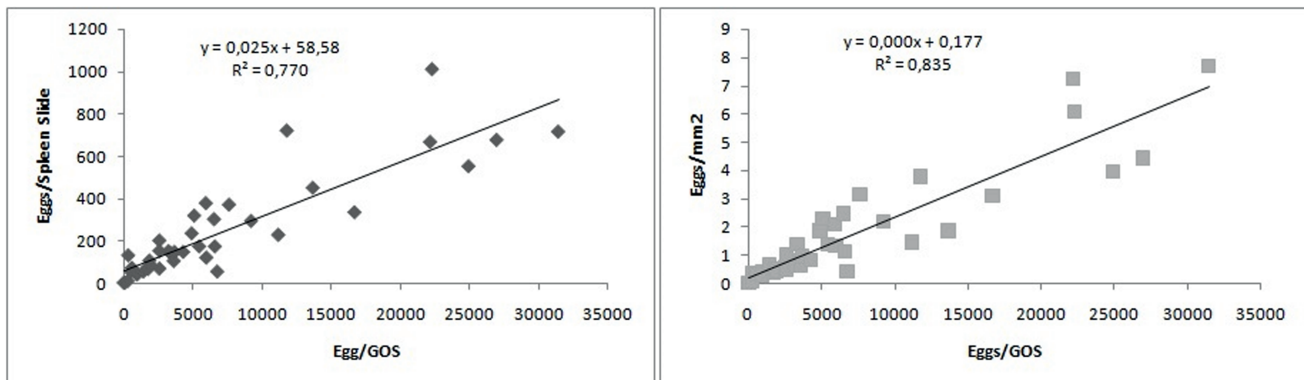


Fig. 1. Linear regression of eggs/gram of spleen (GOS) vs eggs/spleen section (left) or eggs/mm² of tissue section (right).

analyzed. The area of tissues examined ranged from 87,126 to 375,842 mm². Eggs/section correlated less robustly ($r^2=0.770$) to eggs/GOS than eggs/mm² ($r^2 = 0.835$) (Fig. 1).

Discussion

Quantifying eggs/tissue (Goodchild & Dennis, 1967) provides reasonably good correlation with egg burdens assessed as eggs/GOS. However, this method suffers from a lack of standardization in terms of accounting for amount of tissue examined. As amount of tissues placed on slides will vary between studies, this could lead to increased variation and complications when trying to compare egg burdens between studies. In contrast, the correlation between eggs/GOS and eggs/mm² was higher (0.85), but the difference between the two correlations was not statistically significant, so theoretically either method could be used to quantify tissue egg burden in green turtles.

The advantage of standardizing egg burden to tissue area is that it allows for more robust interstudy comparisons by accounting for different amounts of tissues used between studies. It also has the added advantage of reducing subjectivity inherent in more qualitative approaches (Stacy *et al.*, 2010; Flint *et al.*, 2010). Finally, it is less laborious than quantifying eggs/GOS. We thus recommend this technique for those interested in quantifying tissue spirorchiid egg burdens in green turtles.

Conflict of Interest Statement

No financial or personal relationship between the authors and other people or organizations have inappropriately influenced (biased) this work.

Acknowledgments

We are grateful to everyone that supported us in developing this technique. Mention of products or trade names does not imply endorsement by the US Government.

References

AGUIRRE, A., SPRAKER, T., BALAZS, G., ZIMMERMAN, B. (1998): Spirorchidiasis and fibropapillomatosis in green turtles from the Hawaiian islands. *J. Wildl. Dis.*, 34(1): 91 – 98. DOI: 10.7589/0090-3558-34.1.91

BALAZS, G.H., CHALOUPKA, M. (2004): Thirty-year recovery trend in the once depleted Hawaiian green sea turtle stock. *Biol. Cons.*, 117(5): 491 – 498. DOI: 10.1016/j.biocon.2003.08.008

CHAPMAN, P., OWEN, H., FLINT, M., MAGALHÃES, R., TRAUB, R., CRIBB, T., KYAW-TANNER, M., MILLS, P. (2017): Molecular epidemiology and pathology of spirorchiid infection in green sea turtles (*Chelonia mydas*). *Int. J. Parasitol.*, 6(1) 39 – 47. DOI: 10.1016/j.ijppaw.2017.03.001

CHEN, H., KUO, R.J., CHANG, T.C., HUS, C.K., BRAY, R.A., CHENG, I.J. (2012): Fluke (Spirorchiidae) infections in sea turtle stranded on

Taiwan: prevalence and pathology. *J. Parasitol.*, 98(2): 437 – 439. DOI: 10.1645/GE-2875.1

DAILEY, M., MORRIS, R. (1995): Relationship of parasites (Trematoda: Spirorchiidae) and their eggs to occurrence of fibropapillomas in the green turtle (*Chelonia mydas*). *Can. J. Fish. Aquat. Sci.*, 52(S1): 84 – 89. DOI: 10.1139/f95-512

FLINT, M., PATTERSON-KANE, J.C., LIMPUS, C.J., MILLIS, P.C. (2010): Health surveillance of stranded green turtles in southern Queensland, Australia (2006-2009): An epidemiological analysis of causes of disease and mortality. *EcoHealth*, 7(1): 135 – 145. DOI: 10.1007/s10393-010-0300-7

FLINT, M., PATTERSON-KANE, J.C., LIMPUS, C.J., WORK, T.M., BLAIR, D., MILLS, P.C. (2009): Postmortem diagnostic investigation of disease in free-ranging marine turtle populations: a review of common pathologic findings and protocols. *J. Vet. Diagn. Invest.*, 21(6): 733 – 759. DOI: 10.1177/104063870902100601

GLAZEBROOK, J., CAMPBELL, R., BLAIR, D. (1981): Pathological changes associated with cardiovascular trematodes (Digenea: Spirorchiidae) in a green sea turtle *Chelonia mydas*. *J. Comp. Pathol.*, 91(3): 361 – 368. DOI: 10.1016/0021-9975(81)90006-2

GOLDBERG, D., STAHELIN, G., CEGONI, C., WANDERLINDE, J., PAES E LIMA, E., MEDINA, R., RIBEIRO, R., DA SILVA, M., QUEIROZ DE CARVALHO, E. (2013): Case report: Lung Spirorchidiasis in a Green Turtle (*Chelonia mydas*) in Southern Brazil. *Marine Turtle Newsletter*, 139: 14 – 15. Retrieved October 6, 2018 from <http://www.seaturtle.org/mtn>

GOODCHILD, C.G., DENNIS, E.S. (1967): Comparative eggs counts and histopathology in turtles infected with *Spirorchis* (Trematoda: Spirorchiidae). *J. Parasitol.*, 53(1): 38 – 45

GORDON, A., KELLY, W., CRIBB, T. (1998): Lesion Caused by Cardiovascular Flukes (Digenea: Spirorchiidae) in Stranded Green Turtles (*Chelonia mydas*). *Vet. Pathol.*, 35(1): 21 – 30. DOI: 10.1177/030098589803500102

HIRTH, H. (1997, August): Synopsis of biological data on the green turtle *Chelonia mydas* (Linnaeus 1758). *Biological Report*, 97(1): 1 – 120

MARCHIORI, E., NEGRISOLO, E., CASSINI, R., GAROFALO, L., POPPI, L., TESSARIN, C., MARCER, F. (2017): Cardiovascular flukes (Trematoda: Spirorchiidae) in *Caretta caretta* Linnaeus, 1758 from the Mediterranean Sea. *Parasit. Vectors*, 10: 1 – 14. DOI: 10.1186/s13071-017-2396-x

SCHNEIDER, C., RASBAND, W., ELICEIRI, K. (2012): NIH Image to Image J: 25 years of image analysis. *Nat. Methods*, 9(7): 671 – 675

SEMINOFF, J.A. (2004). *Chelonia mydas*. In: IUCN2004. 2004 IUCN Red List of Threatened Species. Retrieved December 20, 2018 from <https://www.iucnredlist.org>. DOI: 10.2305/IUCN.UK.2004.RLTS.T4615A11037468.en

PLATT, T. (2002): Family Spirorchiidae Stunkard. In: Gibson, D., Jones, A., Bray, R. (Eds) *Keys to the Trematoda*. Volume 1. London, UK: CABI Publishing and The Natural History Museum, pp. 453 – 467

RAIDAL, S.R., OHARA, M., HOBBS, R.P., PRINCE, R.I.T. (1998): Gram-

- negative bacterial infections and cardiovascular parasitism in green sea turtles (*Chelonia mydas*). *Aust. Vet. J.*, 76(6): 415 – 417
- RIBEIRO, R.B., JERDY, H., WERNECK, M.R., GOLDBERG, D.W., BIANCHI, M., CARVALHO, E.C.Q. (2017): Parasitic ulcerous caseous gastroesophagitis associated with *Rameshwarotrema uterocrescens* Rao (1975) (Digenea: Pronocephalidae) in a juvenile green turtle (*Chelonia mydas*, Linnaeus 1758 [Testudines: Cheloniidae]): A case report. *J. Parasitol.*, 103(3): 292 – 294. DOI: 10.1645/16-106
- SANTORO, M., MORALES, J.A., STACY, B., GREINER, E.C. (2007): *Rameshwarotrema uterocrescens* trematode parasitism of the oesophageal glands in green sea turtle (*Chelonia mydas*). *Vet. Record*, 160(2): 56 – 60
- SANTORO, M., DI NOCERA, F., IACCARINO, D., LAWTON, S.P., CERRONE, A., DEGLI, U.B., D'AMORE, M., AFFUSO, A., HOCHSCHEID, S., MAFFUCCI, F., GALIERO, G. (2017): Pathology and molecular analysis of *Hapalotrema mistroides* (Digenea: Spirorchiidae) infecting a Mediterranean loggerhead turtle *Caretta caretta*. *Dis. Aquat. Organ.*, 124(2): 101 – 108. DOI: 10.3354/dao03117
- STACY, B., FOLEY, A., GREINER, E., HERBST, L., BOLTEN, A., KLEIN, P., MANIRE, C., JACOBSON, E. (2010): Spirorchiidiasis in stranded loggerhead *Caretta caretta* and green turtles *Chelonia mydas* in Florida (USA): host pathology and significance. *Dis. Aquat. Organ.*, 89(3): 237 – 259. DOI: 10.3354/dao02195
- WERNECK, M.R., NUNES, C., JERDY, H., CARVALHO, E.C.Q. (2017): Loggerhead turtle, *Caretta caretta* (Linnaeus, 1758) (Testudines, Cheloniidae), as a new host of *Monticellius indicum* Mehra, 1939 (Digenea: Spirorchiidae) and associated lesioned to spirorchiid eggs. *Helminthologia*, 54(4): 363 – 368. DOI: 10.1515/helm-2017-0047
- WOLKE, R.E., BROOKS, D.R., GEORGE, A. (1982): Spirorchiidiasis in loggerhead sea turtles (*Caretta caretta*): Pathology. *J. Wildl. Dis.*, 18(2): 175 – 185
- WoRMS EDITORIAL BOARD (2018). World Register of Marine Species. Retrieved October 11, 2018 from <http://www.marinespecies.org>. DOI:10.14284/170
- WORK, T., BALAZS, G., RAMEYER, R., MORRIS, R. (2004): Retrospective pathology survey of green turtles (*Chelonia mydas*) with fibropapillomatosis from the Hawaiian Islands, 1993-2003. *Dis. Aquat. Org.*, 62(1-2): 163 – 176. DOI: 10.3354/dao062163
- WORK, T., BALAZS, G., SCHUMACHER, J., MARIE, A. (2005): Epizootiology of Spirorchiid Infection in Green Turtles (*Chelonia mydas*) in Hawaii. *J. Parasitol.* 91(4): 871 – 876. DOI: 10.1645/GE-454R.1